Egypt. J. Exp. Biol. (Zool.), 13(2): 319- 327 (2017)
DOI: 10.5455/egysebz.20171214034607
© The Egyptian Society of Experimental Biology

RESEARCH ARTICLE

Siham Bayoumi Salem
Donald B. Miles
Abeer Abd-Elhameed Alm-Eldeen
Ramadan Mahmoud Kandyel

# Comparative histological characterization of the tongue in two reptiles, *Scincus scincus* (Scincidae) and *Uromastyx ornata* (Agamidae) in relation to diet

**ABSTRACT:**

The present study is designed to investigate the morphological and histological characterization of the tongue in two reptilian species; *S. scincus* (Insectivorous) and *U. ornata* (Herbivorous). Moreover, to reveal the histochemical features of the lingual glands and connective tissue fibres. Five adult reptiles of each species were used, they were collected from Abo-Rawash, Egypt. Different histochemical methods were used to detect the nature of the lingual gland secretions and their relationship with the feeding habits. Morphologically, in both species, the tongue is somewhat triangle with three distinguishable areas; apex, body, and root. The notched tip is more obvious in *U. ornata*. Different shapes of papillae are distributed over the dorsal lingual surfaces and being more abundant in *U. ornata*. Both serous and mucous secretory acini are noticed in the tongue of *U. ornate,* however, in *S. scincus* only mucous acini are found. The secretory acini showed a clear affinity toward all stain types according to the acid and neutral mucin. The amount and distribution of collagen fibres are comparatively more in the tongue of *U. ornata*. Elastic fibres are not detected in the two-examined species. The results showed a marked variation in lingual papillae, lingual gland secretions, and in the distribution of collagen fibres in the two-examined species as a reflection of their diet.

**KEY WORDS:**

Lingual papillae, Lingual glands, Taste buds, Collagen fibres, Herbivorous

**CORRESPONDENCE:**

Siham Bayoumi Salem

Zoology Department, Faculty of Science, Tanta University, Egypt.

**E-mail:** siham2312@yahoo.com

* Donald B. Miles

Abeer Abd-Elhameed Alm-Eldeen

Ramadan Mahmoud Kandyel

Zoology Department, Faculty of Science, Tanta University, Egypt.

* Department of Biological Sciences, Ohio University, Athens, OH, USA; and 2Ohio Centre for Ecological and Evolutionary Studies, Athens, OH, USA.

**ARTICLE CODE: 34.01.17**

## INTRODUCTION:

The process of feeding is a key factor that affects the ability of an individual to acquire sufficient energy for survival and reproduction (Roth and Wake, 1989; Darwish, 2012; Taha, 2013). Reptile tongue is a muscular organ situated in the oral cavity with some different roles during the process of feeding, including prey capture, food transport, the preparation of bolus, tasting foods, swallowing, and drinking (Schwenk, 2000; Meyers and Herrel, 2005; Schaerlaeken *et al*., 2007).

Several investigations described the morphological characteristics of the reptile tongue and it`s lingual papillae by using light and electron microscopy. Generally, the tongue is divided grossly into the apex, the body, and the root each having different function and histological structure (Herrel *et al*., 1998; Abbate *et al*., 2008). The different lingual papillae differ in shape, size, number, and distribution among different reptiles and these variations might be rely on diet variety, feeding habits and mouth handling of the food

(Iwasaki *et al*., 1985; Darwish, 2012; Nasr *et al*., 2012).

The presence of taste buds are noted in reptile lingual epithelium (Herrel *et al*., 1998; Wassif, 2002; Abbate *et al*., 2008; Elsheikh *et al*., 2013; Sarhan and Hussein, 2013).The existence of taste buds on different tongue regions may play an important role in receiving chemical and mechanical information of food (Nasr *et al*., 2012).

Moreover, numerous authors mentioned the functional lingual glands in different species and their significant role during feeding process, especially in food movements, transport, and swallowing (Wassif and El-Hawari, 1998; Josef Beisser *et al*., 2004; Koca *et al*., 2007; Elsheikh *et al*., 2013). The present study designed to illustrate the structures of the dorsal lingual surface of two squamate reptiles belong to two different families; Scincidae and Agamidae in relation to their feeding habitats

## MATERIAL AND METHODS:

Ten adult reptiles are obtained: five *Scincus scincus*; Linnaeus, 1758, belong to family Scincidae, and five *Uromastyx ornata*; Heyden, 1827, related to family Agamidae. Specimens are collected from Abo-Rawash district, Egypt. Each specimen is sacrificed following IACUC (Institution of Animal Care and Use Committee) protocols, heads are decapitated, the tongues were immediately removed from the buccal cavity and immersed in 10% neutral buffered formal saline. By using a Leica GZ7 Stereomicroscope at 40X, provided by digital camera (VAN GUARD 122-CDPC-5); the tongue length (TL), apical width (AW), body width (BW), and root width (RW) by using ImageJ software (Ferreira and Rasband, 2012).

Also measured the papillae height, width, thickness, and glands diameter by ImageJ analysing software. The selected images of the three lingual parts are examined and quantified by detecting five randomly image fields. The measurements are calculated the means ± SD and computed for statistical comparison between the two species.

Histologically, the tongues were removed and immediately fixed in 10% formalin for 48 hours, dehydrated in ascending ethanol series, cleared then embedded in paraffin wax. Five µm sections were stained by haematoxylin and eosin for examination of the general histology. Alcian Blue (Spicer and Meyer, 1960) for acidic mucin; Periodic Acid-Schiff (Humason, 1962) for neutral mucin, and double stain of Alcian blue (pH = 2.5) and periodic Acid-Schiff (AB-PAS) technique for acidic and neutral mucin (Mowry, 1956). For staining the collagen and muscle fibres we used Masson's trichrome (Luna, 1968) for elastic fibres detection; Verhoeff's van Gieson, Modified Verhoff's (Verhoeff, 1908), Weigert's resorcin-fuchsin, and Orcein stain are used. The sections were examined and photographed under bright field light microscope (Olympus BX 50 compound microscope).

## RESULTS:

Morphologically, the tongue specimens have a triangle shape with bifurcate pointed tip and widely broad bases. It consists of three parts, the apex, body, and root with a well-developed posterior limb in *S. scincus* (Fig. 1 A& B).

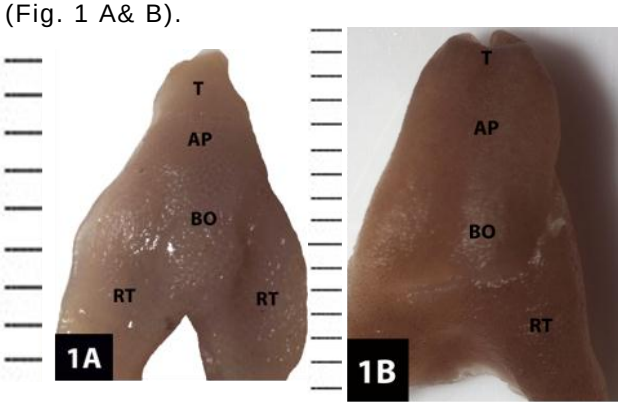


Fig. 1. Photomicrograph of dorsal view of tongue showing the apex (AP), the body (BO), root (RT), and tip (T).

*A) S. scincus*, B) *U. ornata*

Morphometric analysis cleared that the tongue of *U. ornata* represents the largest length; 1.56 ± 0.05 cm length; and width in the three regions; 0.38 ± 0.02 cm in apex; 0.75 ± 0.04 cm in body, and 1.03 ± 0.03 cm in root. In contrast, the *S. scincus* showed 0.96 ± 0.08 cm length, 0.18 ± 0.01 cm, 0.63 ± 0.03 cm, and 0.61 ± 0.03 cm width at the three different parts, respectively (Table 1 & Fig. 2 A& B).

Table 1. Measurements of the tongue length (TL), apex width (AW), body width (BW), and root width (RW) in the tongue of *S. scincus* and *U. ornata*.

| Species | TL | AW | BW | RW |
|---|---|---|---|---|
| *S. scincus* | 0.96 ± 0.08 | 0.18 ± 0.01 | 0.63 ± 0.03 | 0.61 ± 0.03 |
| *U. ornata* | 1.56 ± 0.05 | 0.38 ± 0.02 | 0.75 ± 0.04 | 1.03 ± 0.03 |

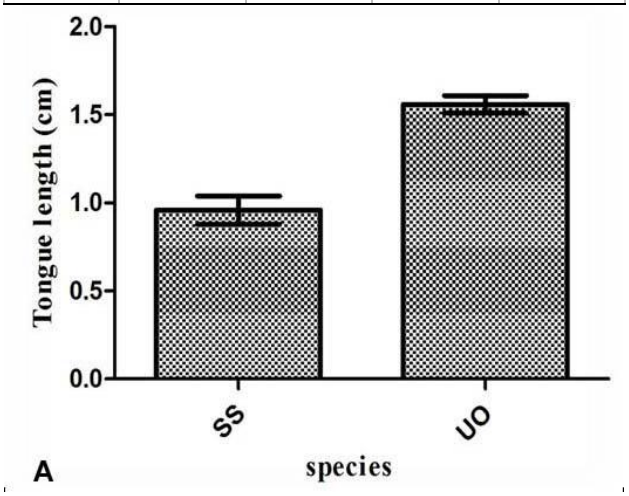

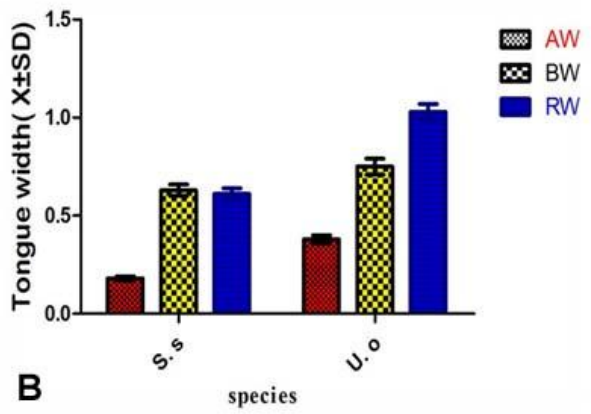


Fig. 2. Mean length of the tongue of *S. scincus* (Ss), and *U. ornata* (Uo). B. Mean apical widths (AW), body width (BW), root width (RW) of *S. scincus* (Ss), and *U. ornata* (Uo).

The papillae height mean averages of the three regions of the tongue are; 193.4 ± 8.7 µm in apex, 274.5 ± 29 µm in body, 277.4 ± 47 µm in root in the *U. ornata*. On other hand, the papillae height of *S. scincus* are 153 ± 6.5 µm in apex, 174 ± 22.2 µm in body, 178 ± 7.3 µm in root (Table 2 & Fig. 3). The mean width of lingual papillae in *U. ornata* is the maximal average, on contrast in *S. scincus* the minimal value is listed (Table 2 & Fig. 4). The largest thickness of the mucosal papillae in the three regions of the dorsal surface of the tongue of *U. ornata* were 29.3 ± 8.03 µm, 62.8 ± 7.6 µm, 47.6 ± 16.3 µm, while the lowest thickness is noted in the tongue of *S. scincus*; 27 ± 6.1 µm, 26 ± 7.0 µm, 27 ± 2.7 µm (Table 2 & Fig. 5). Higher diameters of the lingual glands are noted in the three regions of the tongue of *U. ornata*, the diameters of the glands are increased backward towards the root region. where, in *S. scincus* the glands are absent in the apex and are represented at the body and root regions with diameters 70.1 ± 6.3 µm and 82.2 ± 21.8 µm, respectively (Table 2 & Fig. 6).

Table 2. Morphometry of lingual papillae and gland diameter.

| species | Height of papillae | | | Width of papillae | | | Thickness of papillae | | | Diameter of glands | | |
|---|---|---|---|---|---|---|---|---|---|---|---|---|
| | Apex | Body | Root | Apex | Body | Root | Apex | Body | Root | Apex | Body | Root |
| *S. s* | 153.2 ± 6.5 | 174.5 ± 22.2 | 178 ± 7.3 | 68 ± 8.4 | 123 ± 8.4 | 67 ± 27.0 | 27.1 ± 6.1 | 26 ± 7.0 | 27 ± 2.7 | 0 | 70.1 ± 6.3 | 83.2 ± 21.8 |
| *U. o* | 193.4 ± 8.7 | 274.5 ± 29 | 277.4 ± 47 | 153 ± 14.5 | 139 ± 34.6 | 153 ± 26.6 | 29.3 ± 8.03 | 62.8 ± 7.6 | 47.6 ± 16.3 | 91.1 ± 10 | 108.9 ± 16.2 | 131 ± 36.3 |

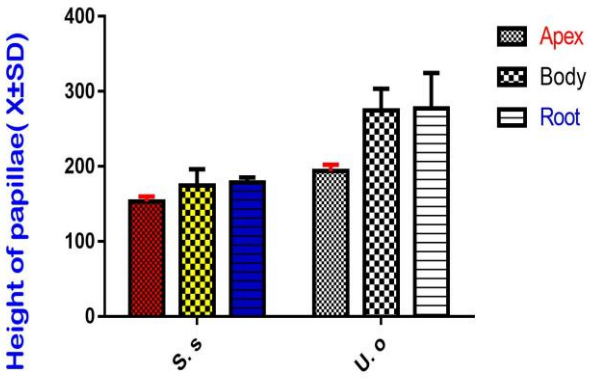


Fig. 3. Mean average of the heights of lingual papillae of *S. Scincus* (S. s), and *U. Ornata* (U.o).

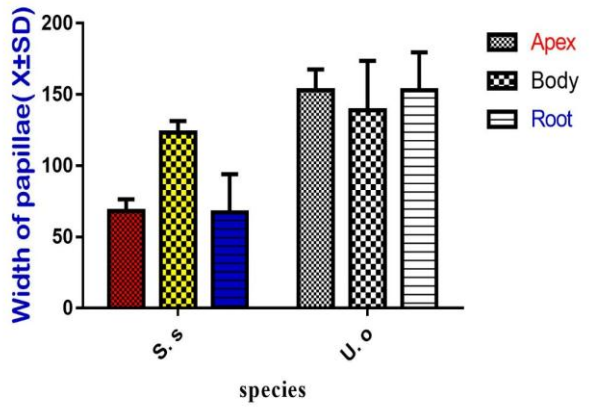


Fig. 4. Mean average of the width of lingual papillae of *S. Scincus* (S. s), and *U. Ornata* (U.o).

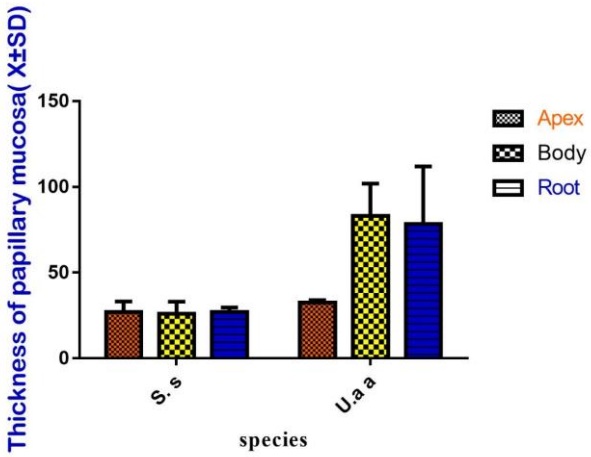


Fig. 5. Mean average of the thickness of papillary mucosa of *S. Scincus* (S. s), and *U. Ornata* (U.o).

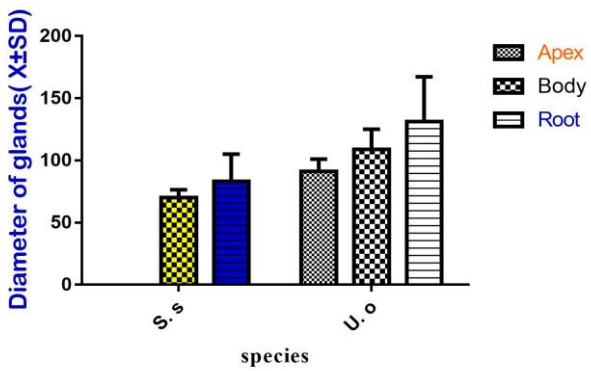


Fig. 6. Mean average of the diameter of the lingual glands of *S. Scincus* (S. s), and *U. Ornata* (U.o).

In both studied species, the three different lingual regions consist of three major histological layers: mucosa, lamina propria, and muscularis. In *S. scincus*, short leaf-like papillae are distributed over the dorsal surface of the apex part of the tongue. They are bent backwardly and are covered by thin layer of stratified squamous epithelium. The lamina propria appears as a thin layer of dense connective tissue containing muscles fibres arranged in several directions and penetrates deeply into the papillae cores. Few taste buds are houses the dorsal epithelium of the papillae (Fig. 7). Whereas, Lingual glands are absent.

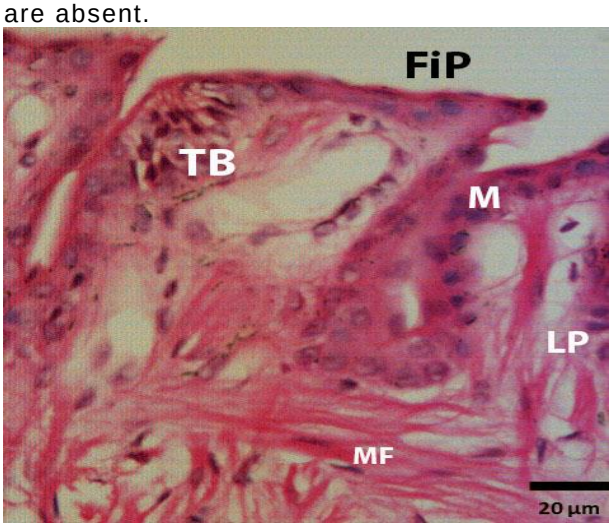


Fig. 7. Photomicrograph of a longitudinal section of *S. Scincus* lingual Apex, showing filiform papillae (FiP), mucosa (M), lamina propria (LP), taste bud (TB), and muscle fibres (MF). Stain: H&E.

The dorsal epithelium of the lingual body of the *S. scincus* possesses many paddles like papillae which have a tight stalk and broad surface. Few taste buds are found on the superior surface of the mucosal layer. Moreover, numerous lingual glands are observed at the base of the papillae stalk (Fig. 8). These glands gave a moderate faint with Alcian Blue (AB) staining and strong positive reaction with PAS (Fig. 9). The reaction revealed the presence of both acidic and neutral mucin secretions.

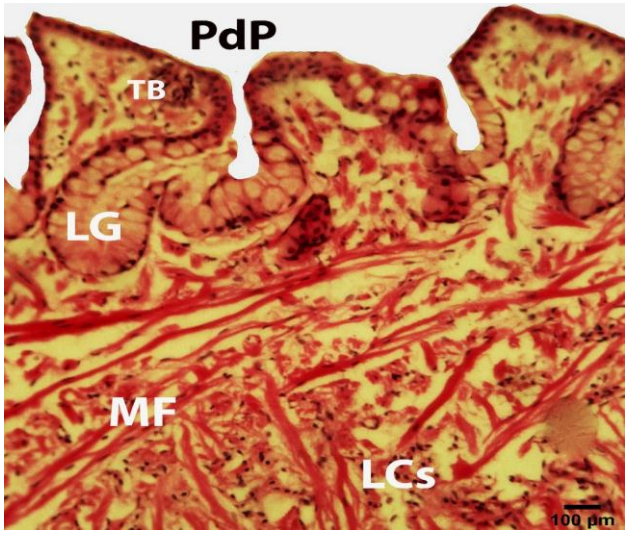


Fig. 8. Photomicrograph of a longitudinal section of S. Scincus lingual Body, showing paddle like papillae (PdP), taste bud(TB), lingual glands(LG), muscle fibres (MF), and lymphoid cells(LCs). Stain: H&E.

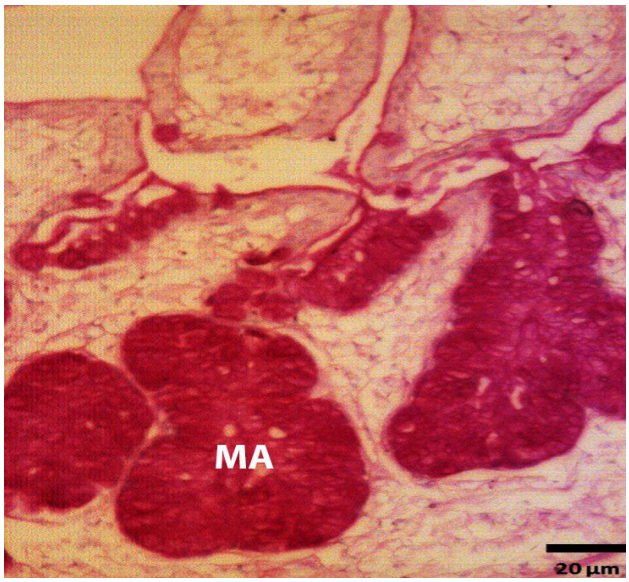


Fig. 9. Photomicrograph of lingual mucous acini (MA) of the *S. scincus* lingual body showing positive neutral mucin reaction. Stain: PAS.

The dorsal surface of the lingual root bears numerous filiform papillae. Abundant mucous acini are noted at the lamina propria (Fig. 10). Mucous cells contents stained dark with Alcian Blue (AB) staining (Fig. 11), dark red with PAS, and blue-red with double stains Alcian Blue (AB) and periodic acid shiff (PAS) indicating the presence of both acidic and neutral mucin. Collagen fibres are sparsely distributed and restricted underneath the basement membrane of the lingual mucosa and also appeared as thin and thick bundles in several directions surrounded the mucous acini (Fig. 12).

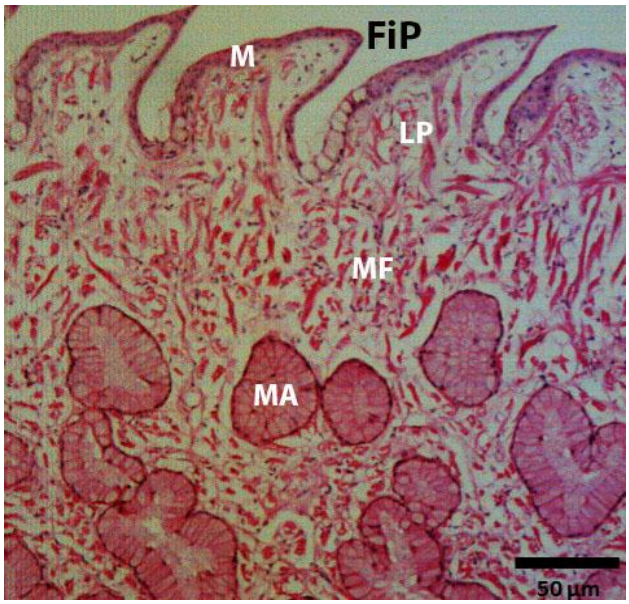


Fig. 10. Photomicrograph of longitudinal section of *S. Scincus* lingual Root, showing filiform papillae (FiP), mucosa (M), lamina propria (LP), mucous acini (MA), and muscle fibres (MF). Stain: H&E.

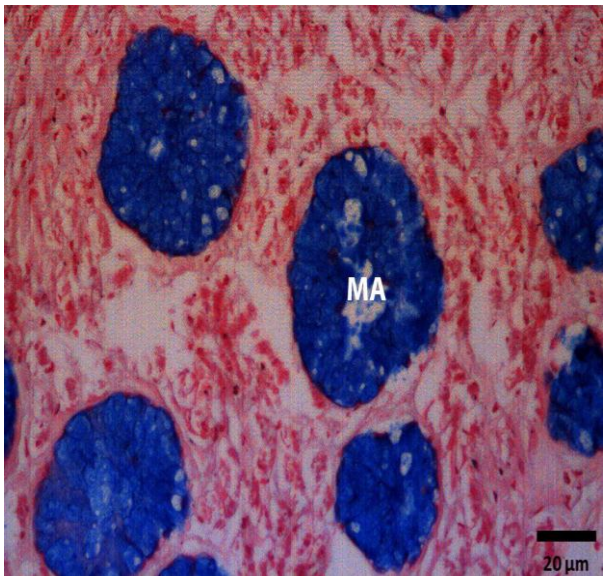


Fig. 11. Photomicrograph of lingual mucous acini (MA) of the *S. scincus* lingual root showing strong acidic mucin reaction. Stain: AB.

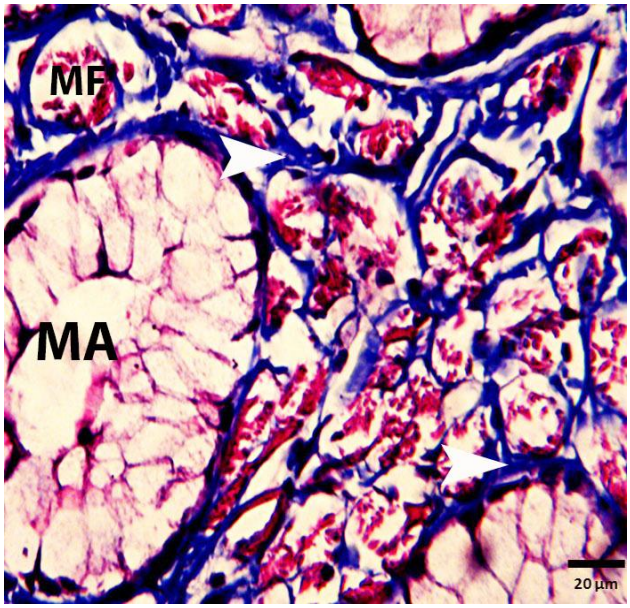


Fig. 12. Photomicrograph of a longitudinal histological section of the dorsal lingual mucosa of *S. scincus* showing mucous acini (MA), muscle fibres (MF), and collagen fibre (head arrows). Stain: Masson Trichrome.

In *U. ornata*, two forms of papillae are detected; broad and conical shape that distributed over the dorsal surface of the lingual apex. Excessive Serous secretory acini are invading the lamina propria layer. The acini showed a remarkable variation in their size and disjointed by thin bundles of connective tissue richly supplied with capillary vessels. The serous acini cells are short columnar with ovo-basal densely stained nuclei, its lumen is wide and filled with their secretion (Fig. 13). However, the lingual body epithelium exhibits few taste buds and notable taste pore. The serous lingual acini contents have a negative reaction with AB, while gave red colour with PAS (Fig. 14) as indication of neutral mucin.

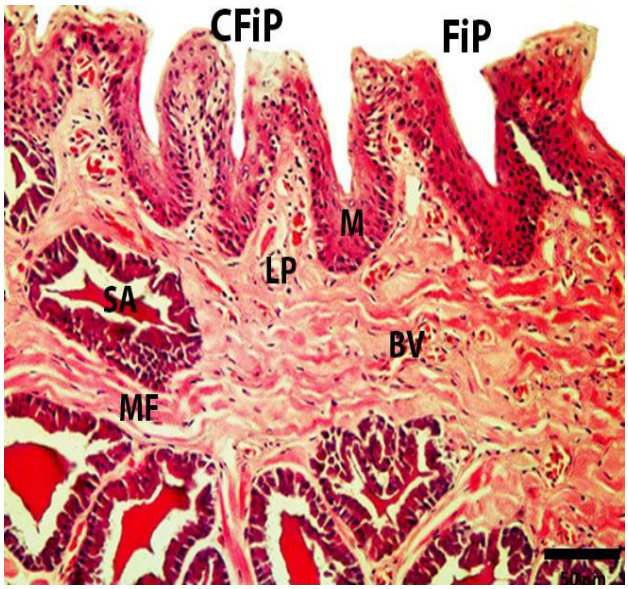


Fig. 13. Photomicrograph of a longitudinal section of *U. ornata* lingual Apex, showing filiform papillae (FiP), conical papillae (CP), mucosa (M), lamina propria (LP), Serous acini (SA), muscle fibres (MF), and lymphatic space (LPs). Stain: H&E.

The anterior part of lingual root is covered by tall filiform papillae while posteriorly, it is decorated by cubical form aggregation of some blood vessels and lymphatic cells that invading their core (Fig. 15). The mucous acini are in the root part, while the serous acini are absent. The mucous secretions are acidic and neutral mucin, as reacted by the specific stains (Fig. 16). The collagen fibres are more distinctly scattered and fill the papillary core (Fig. 17), and around the serous acini (Fig. 18), as well as at the connective tissue that surrounded the mucous acini (Fig. 19). The tongue of the two-examined species, failed to establish the presence of elastic fibres by using a different specific stain (Fig. 20).

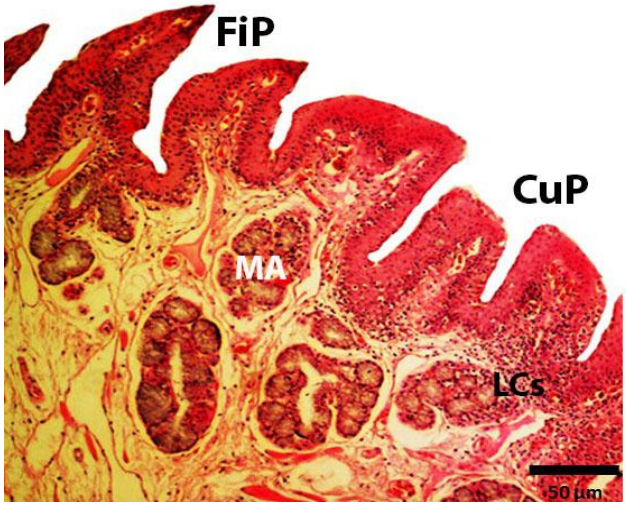


Fig. 15. Photomicrograph of a longitudinal histological section of root lingual mucosa of *U. ornata*, showing filiform papillae (FiP), cuboidal papillae (CuP), and mucous acini (MA), and lymphoid cells (LCs). Stain: H&E.

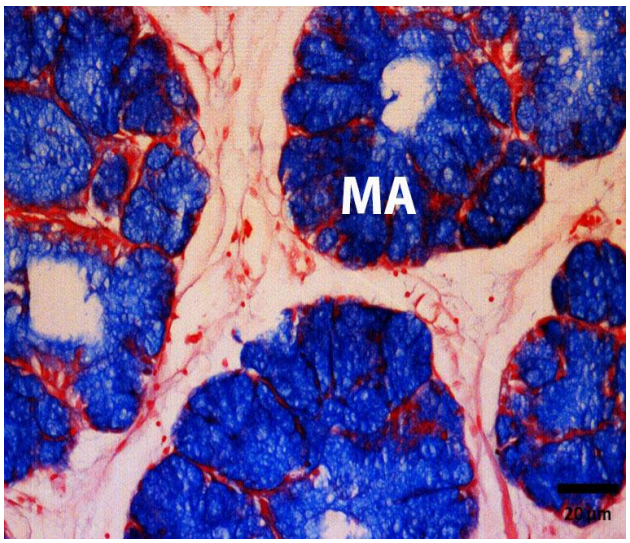


Fig. 16. Photomicrograph of lingual mucous acini (MA) of the *U. ornata* lingual root showing strong acidic mucin reaction. Stain: AB.

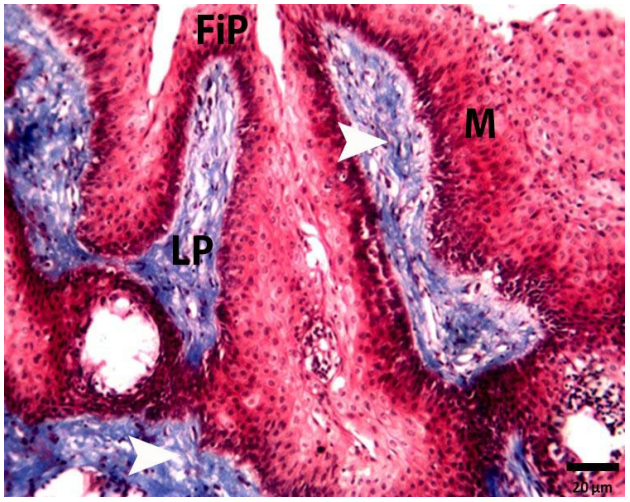


Fig. 17. Photomicrograph of longitudinal histological section of the dorsal lingual surface of *U. ornata* showing filiform papillae (FiP), mucosa (M), lamina propria (LP), and collagen fibre (head arrows). Stain: Masson Trichrome.

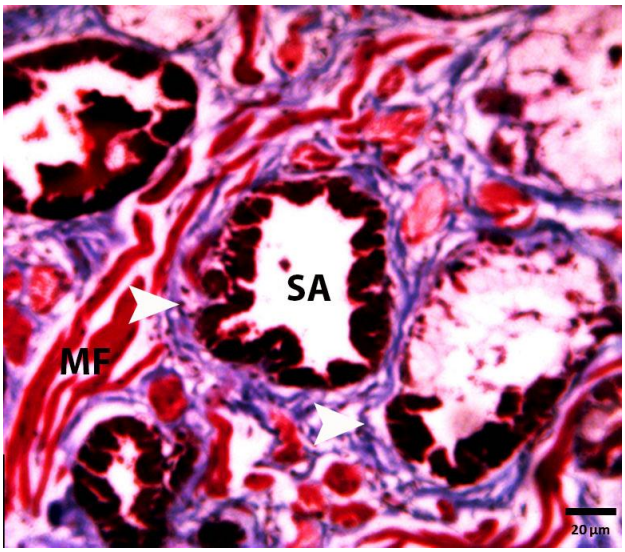


Fig. 18. Photomicrograph of longitudinal histological section of the dorsal lingual surface of *U. ornata* showing serous acini (SA), muscle fibres (MF) and collagen fibre (head arrows). Stain: Masson Trichrome.

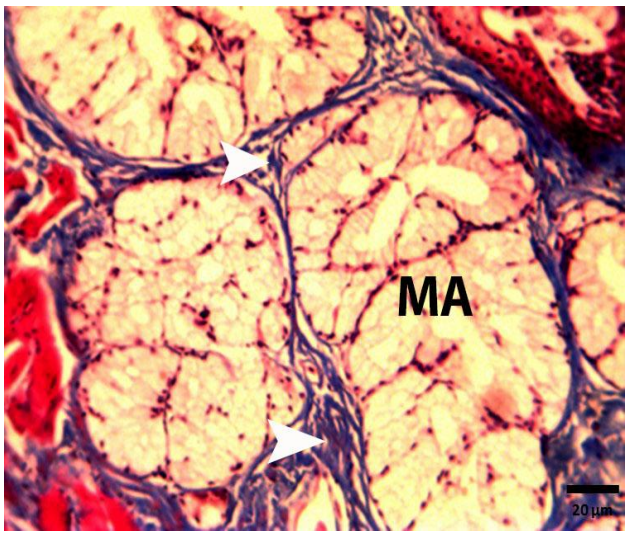


Fig. 19. Photomicrograph of longitudinal histological section of the root dorsal lingual surface of *U. ornata* showing mucous acini (MA), and collagen fibre (head arrows). Stain: Masson Trichrome.

Fig. 20. Photomicrograph of a longitudinal section of *U. ornata* showing; mucous acini (MA), collagen fibers (head arrows). Stain: Weigert's resorcin-fuchsin.

## DISCUSSION:

Three grossly defined lingual regions (apex, body, and root) are distinguished in the two-examined species. This finding evenly matched with Delheusy *et al*. (1994) in *Oplurus cuvieri*, Abbate *et al.* (2008) in *Iguana iguana*, Darwish (2012) in *Ptyodactylus guttatus* and *Stenodactylus petrii*, and Zghikh *et al*. (2014) in *Pogona vitticeps*. Many authors recorded that the tongue is divided into three main areas that reflect the multiple functions of the tongue in feeding process during food ingestion, intrabuccal transport, and swallowing (Delheusy *et al*., 1994; Iwasaki, 2002; Abbate *et al*., 2008), While McDowell (1972) reflected this subdivision into functional and evolutionary basis

in contrast, Jamniczky *et al*. (2009) divided the tongue of *Eublepharis macularius* into five distinctive morphological regions, each has a distinguishing morphological and histological structure.

In the present investigation, the tongue in both species showed bifurcated tip that is more obvious in *U. ornata*. This bifurcation is correlated with the ability to follow scent trails using the vomeronasal system mediated. Schwenk (1994 & 2000), and Darwish (2012) mentioned that feeding habit in bifurcated insectivores lizards reflect that the insect may be swallowed, and bifurcation may facilitate this process. On the contrary, Estes *et al*. (1988) reported that there is no a strong relationship between the tongue bifurcation and the feeding habitat, but they referred to reptiles phylogeny.

In *S. scincus*, the posterior limb of the tongue root is well developed. Numerous investigations described the existence of this well-developed posterior tongue limb; Bramble and Wake, (1985) in some terrestrial turtles, Mohammed (1991) in Gekkonidae, Iwasaki (1990) in *Gekko japonicus*, and Wassif (2002) in *Chalcides ocellatus*. The authors proposed that the presence of the well-developed posterior limb is to push the food into the oesophagus during swallowing. On the other hand, Schwenk (1986) demonstrated that this structure may also relate to a greater degree of tongue protrusion.

The present work revealed different forms of lingual papillae with a backward oriented tip, these papillae may help in movement of the food toward the pharynx (Iwasaki, 2002). The papillae are widely spread over the lingual dorsal surfaces of the two-examined species; they take different shapes; filiform, cubical, conical, and paddle-like shape. Similar findings were recorded by Shimada *et al*. (1990) in *Alligator mississippiensis*; El-Sayyad *et al*. (2011) in *Tarentola annularis* and *Crocodylus niloticus* and Sarhan and Hussein (2013) in *Chalicides ocellatus*. The function of these papillae is to help in food transport, swallowing and provides tongue with a rough surface suited for the movement of food (Trzcielińska-Lorych *et al.*, 2009; Karan *et al*., 2011; Nasr *et al*., 2012).

Few taste buds are noticed over the lingual apical and body parts of the tongue of *S. Scincus,* while they are present only in the body region of U*. ornata*. Nasr *et al*. (2012) mentioned that the presence of taste buds on the tongue tip of the rat may play an important role in receiving chemical and mechanical information of food. On other hand, some authors failed to detect taste buds in *Eublepharis macularius* (Jamniczky *et al*., 2009), in *Podarcis sicula* (Abbate *et al*., 2010), and in *Ptyodactylus guttatus* and *Stenodactylus petrii* (Darwish, 2012).

Both mucous and serous acini are detected in the tongue of *U. ornata* while only the mucous acini are observed in the *S. scincus*. The mucus secretion is adaptive modifications related to the food and feeding ecology of the insectivorous *S. scincus*. While the serous acini produce watery fluid contains certain digestive enzymes (amylase) that help to digest the vegetable food. The serous secretion is thought to increase the enzymatic action in the oral cavity of the herbivore *U. ornata* because it has difficult in the digestion plant material and they don't chew their food (Szarski, 1962; Ostrom, 1963) in herbivorous lizards, and Sokol (1971) in reptiles). The existence of both mucous and serous glands in *U. ornata* were also noticed in the lingual body of *Laudakia stellio* (Koca *et al*., 2007), and in *Pogona vitticeps* (Zghikh *et al*., 2014). The density of the acidic and neutral mucin is different in the tongue of both species. These may be due to the different nutritional habits. Delheusy *et al*. (1994) revealed that the mucous secretions may have a significant function in the prey capturing. In addition, the neutral mucin may aid in food lubrication to facilitate swallowing and maintain the lingual hydration.

In the present study, a well-developed connective tissue rich with collagen fibres is detected in the tongue of *U. ornata*. The intensive incidence of collagen fibres in *U. ornata* reflects a success adaptation to the herbivorous diet. collagen fibres may help in the attachment between the muscle fibres and the epithelia of lingual papillae (Rabinowitz and Tandler, 1986), and may play crucial role in its elongation and direction (Kier and Smith, 1985). These observations are coincided with the report of Herrel *et al*. (2001) who reported that the arrangement of collagen fibres facilitate limited muscle elongation in chameleon. De Groot and van Leeuwen (2004) credited the tongue prehension of *Chamaeleo melleri* and *Cantherhines pardalis*, to collagen fibres and accelerator muscle.

Elastic fibre is a structural glycoprotein that helps in preserving the tissue elasticity (Gosline *et al*., 2002). The present failed to detect elastic fibres in the tongue of the two-reptile species. However, few studies described elastic fibres in the tongue of some mammals and birds. Yamamoto *et al*. (1989) cleared the distribution of elastic fibres in the filiform papillae of *Suncus murinus,* and concluded that the regional distribution of this structure may reflect the variance of mechanical strength between the tongue are as caused by tongue movement during mastication. Kobayashi *et al*. (1998) observed several filaments of elastic fibres in the penguin lingual papillae.

**REFERENCES:**

Abbate F, Guerrera M, Montalbano G, Zichichi R, Germanà A, Ciriaco E. 2010. Morphology of

the lingual dorsal surface and oral taste buds in Italian lizard (*Podarcis sicula*). Anat. histol. embryol., 39(2): 167-171.

Abbate F, Latella G, Montalbano G, Guerrera M, Levanti M, Ciriaco E. 2008. Scanning electron microscopical study of the lingual epithelium of green iguana (Iguana iguana). Anat. histol. embryol., 37(4): 314-316.

Bramble DM, Wake DB. 1985. Feeding mechanisms of lower tetrapods. In: "Functional vertebrate morphology. (Hildebrand M, Bramble DM, Liem KF, Wake DB. Eds)". Harvard University Press, Cambridge, MA, pp 230–261.

Darwish ST. 2012. Comparative histological and ultrastructural study of the tongue in Ptyodactylus guttatus and Stenodactylus petrii (Lacertilia, Gekkonidae). J. Am. Sci., 8(2): 603-612.

De Groot JH, van Leeuwen JL. 2004. Evidence for an elastic projection mechanism in the chameleon tongue. Proc. Biol Sci., 271(1540): 761–770.

Delheusy V, Toubeau G, Bels VL. 1994. Tongue structure and function in *Oplurus cuvieri* (Reptilia: Iguanidae). Anat. Rec., 238(2): 263-276.

El-Sayyad HI, Sabry DA, Khalifa SA, Abou-El-Naga AM, Foda YA. 2011. Studies on tongue of reptilian species *Psammophis sibilans, Tarentola annularis* and *Crocodylus niloticus*. Int. J. Morphol., 29(4): 1139-1147.

Elsheikh E, Atta K, Al-Zahaby SA. 2013. Comparative study on the tongue of Bufo regularis and Chalcides ocellatus in relation to their habitats. J. Basic Appl. Zool., 66(3): 131-138.

Estes R, De Queiroz K, Gauthier J. 1988. Phylogenetic Relationships of the Lizard Families: Essays Commemorating Charles L. Camp. (Estes R, Pregill G. Ed.). Stanford Univ Press, Stanford, CA, pp. 631.

Ferreira T, Rasband W. 2012. ImageJ user guide. IJ1. 46r. Natl. Inst. Health, Bethesda, MD. http://rsb. info. nih. gov/ij/docs/guide/user-guide. pdf.

Gosline J, Lillie M, Carrington E, Guerette P, Ortlepp C, Savage K. 2002. Elastic proteins: biological roles and mechanical properties. Philos. T. Roy. Soc. B, 357(1418): 121-132.

Herrel A, Aerts P, De Vree D. 1998. Static biting in lizards: functional morphology of the temporal ligaments. J. Zool., 244(1): 135-143.

Herrel A, Meyers JJ, Nishikawa KC, De Vree F. 2001. Morphology and histochemistry of the hyolingual apparatus in chameleons. J .Morphol., 249(2): 154–170.

Humason GL. 1962. Animal tissue techniques. Animal tissue techniques. W. H. Freeman and Company, pp. 468.

Iwasaki S, Miyata K, Kobayashi K. 1985. Fine structure of the oral epithelial cell surface in the Japanese lizard, *Takydromus tachydromoides*. Jpn. J. Oral Biol., 27(3): 956-964.

Iwasaki S. 1990. Fine structure of the dorsal lingual epithelium of the lizard, *Gekko japonicus* (Lacertilia, Gekkonidae). Am. J. Anat., 187(1): 12-20.

Iwasaki S. 2002. Evolution of the structure and function of the vertebrate tongue. J. Anat., 201(1): 1-13.

Jamniczky H, Russell A, Johnson M, Montuelle S, Bels V. 2009. Morphology and histology of the tongue and oral chamber of (Squamata: Gekkonidae), with special reference to the foretongue and its role in fluid uptake and transport. Evol. Biol., 36(4): 397-406.

Josef Beisser C, Lemell P, Weisgram J. 2004. The dorsal lingual epithelium of *Rhinoclemmys pulcherrima incisa* (Chelonia, Cryptodira). Anat. Rec. A, Discov. Mol. Cell Evol. Biol., 277(1): 227-235.

Karan M, Yilmaz S, Aydin A. 2011. Morphology of the filiform lingual papillae in porcupine (*Hystrix cristata*). Anat. Histol. Embryol., 40(2): 100-103.

Kier WM, Smith KK. 1985. Tongue, tentacles and trunks: the biomechanics of movement in muscular-hydrostats. Zool. J. Linn. Soc., 83(4): 307-324.

Kobayashi K, Kumakura M, YoshimuraK, Inatomi M, Asami T. 1998. Fine structure of the tongue and lingual papillae of the penguin. Arch. Histol.Cytol., 61(1): 37-46.

Koca YB, Oğuz EO, Osanç E. 2007. Morphology, and muscle-and papilla-volume ratios, of the tongue of Laudakia stellio (Agamidae, Squamata): a histological and stereological study. Zool. Sci., 24(9): 899-905.

Luna LG. 1968. Manual of histologic staining methods of the Armed Forces Institute of Pathology. New York : Blakiston Division, McGraw-Hill, pp. 258.

McDowell SB. 1972. The evolution of the tongue of snakes, and its bearing on snake origins. In: "Evolutionary biology. (Hecht MK, Dobzhansky T, Steere WC. Eds)". Vol. 6. Springer, Boston, MA, pp. 191–273.

Meyers JJ, Herrel A. 2005. Prey capture kinematics of ant-eating lizards. J. Exp. Biol., 208(Pt 1): 113-127.

Mohammed MBH. 1991. The structure of the tongue in certain Geckos (Gekkonidae: Reptilia). J. Egypt. Ger .Soc. Zool., 6(B): 289-314.

Mowry RW. 1956. Alcian blue technics for the histochemical study of acidic carbohydrates. J. Histochem. Cytochem., 4: 407.

Nasr ES, Gamal AM, Elsheikh EH. 2012. Light and scanning electron microscopic study of the dorsal lingual papillae of the rat *Arvicanthis niloticus* (Muridae, Rodentia). J. Am. Sci., 8(4): 619-627.

Ostrom JH. 1963. Further comments on herbivorous lizards. Evolution, 17: 368-369.

Rabinowitz T, Tandler B. 1986. Papillary morphology of the tongue of the American chameleon: *Anolis carolinensis*. Anat. Rec., 216(4): 483-489.

Roth G, Wake D. 1989. Conservatism and innovation in the evolution of feeding in vertebrates. In: "Complex Organismal Functions: Integration and Evolution in Vertebrates. (Wake DB, Roth G. Eds)". New York: John Wiley & Sons, pp. 7–21.

Sarhan OMM, Hussein RM. 2013. Ultrastructural Studies on the Tongue of Some Egyptian Lizards 1-Scincine Lizards *Chalcides Oscellatus* and *Chalcides Sepsoides* (Lacertilia, Scincidae). J .Cytol. Histol., 3(7): 2-10 .

Schaerlaeken V, Meyers JJ, Herrel A. 2007. Modulation of prey capture kinematics and the role of lingual sensory feedback in the lizard *Pogona vitticeps*. Zoology (Jena), 110(2): 127-138.

Schwenk K. 1986. Morphology of the tongue in the tuatara, *Sphenodon punctatus* (Reptilia: Lepidosauria), with comments on function and phylogeny. J. Morpho., 188(2): 129-156.

Schwenk K. 1994. Why snakes have forked tongues. Science, 263(5153): 1573-1577.

Schwenk K. 2000. Feeding in lepidosaurs. In: "Feeding: Form, function and evolution in tetrapod vertebrates. (Schwenk K. Ed.)". Academic Press, London, pp. 175-291.

Shimada K, Sato I, Yokol A, Kitagawa T, Tezuka M, Ishii T. 1990. The fine structure and elemental analysis of keratinized epithelium of the filiform papillae analysis on the dorsal tongue in the American alligator (*Alligator mississippiensis*). Okajimas Folia Anat. Jpn., 66(6): 375-391.

Sokol OM. 1971. Lithophagy and geophagy in reptiles. J. Herpetol., 5(1/2): 69-71.

Spicer S, Meyer D. 1960. Histochemical differentiation of acid mucopolysaccharides by means of combined aldehyde fuchsin-alcian blue staining. Tech. Bull. Regist. Med. Technol., 30: 53-60.

Szarski H. 1962. Some remarks on herbivorous lizards. Evolution, 16(4): 529-529.

Taha A. 2013. Comparative anatomical, histological and histochemical study of tongue in two species of insectivorous vertebrates. Aust. J. basic Appl. Sci., 7(1): 401-410.

Trzcielińska-Lorych J, Jackowiak H, Skieresz-Szewczyk K, Godynicki S. 2009. Morphology and morphometry of lingual papillae in adult and newborn Egyptian fruit bats (*Rousettus aegyptiacus*). Anat. Histol. Embryol., 38(5): 370-376.

Verhoeff FH. 1908. Some new staining methods of wide applicability, including a rapid differential stain of elastic tissue. JAMA, 11: 876-877.

Wassif ET. 2002. Ultrastructure of the lingual epithelium of adult scincine lizard *Chalcides ocellatus*. Egyp. J .Biol., 4: 76–86.

Wassif I, El-Hawari M. 1998. Scanning electron microscopy of the dorsal lingual epithelium of the golden lizard; *Eumeces schneideri*, Reptilia: scincidae. J. Egypt. Ger. Soc. Zool., 26(C): 11–30.

Yamamoto T, Kondo S, Nagai H. 1989. On the distribution of elastic fibers in the filiform papillae of *Suncus murinus*. Jpn. J. Oral Biol., 31(4): 379-384.

Zghikh LN, Vangysel E, Nonclercq D, Legrand A, Blairon B, Berri C, Bordeau T, Rémy C, Burtéa C, Montuelle SJ, Bels V. 2014. Morphology and fibre-type distribution in the tongue of the *Pogona vitticeps* lizard (Iguania, Agamidae). J. Anat., 225(4): 377-389.

## الصفات المورفولوجية والنسيجية المقارنة للسان في الدفان والضب الملون وعلاقتهما بنوع الغذاء

**سهام بيومي سالم، دونالد بيلي مايلز*، عبير عبد الحميد علم الدين، رمضان محمود قنديل**

قسم علم الحيوان، كلية العلوم، جامعة طنطا، مصر

* قسم العلوم البيولوجية، جامعة اوهايو، الولايات المتحدة الأمريكية

أجريت الدراسة على نوعان من الزواحف المصرية وهما الدفان والضب الملون، ولقد تم فحص الشكل الظاهري للسان في النوعين، وتم قياس طول اللسان وسمكه وكذلك تم قياس ارتفاع وسمك الحلمات اللسانية في المناطق المختلفة للسان، أيضا تم قياس سمك الطبقة المخاطية للحلمات اللسانية وقطر الغدد اللسانية. أوضحت الدراسة الهستولوجية للطبقة المخاطية الظهرية للسان على وجود العديد من الحلمات اللسانية مختلفة الأشكال وأيضا وجود غدد مصلية وأخرى مخاطية وذلك باستخدام صبغات هستوكيميائية عديدة. أظهرت هذه النتائج أن الاختلافات الشكلية والنسيجية للسان في كل من الحيوانين قد يرجع الي اختلاف عاداتهم الغذائية وقد تساهم هذه النتائج في إضافة بعض المعلومات عن تركيب وتشريح لسان نوعين من الزواحف المنتشرة في مصر.