Egypt. J. Exp. Biol. (Zool.), 11(1): 61 – 69 (2015)

RESEARCH ARTICLE

Mohamed SA. El-Gerbed

HEPATOPROTECTIVE EFFECT OF VITAMIN C ON CAPECITABINE-INDUCED LIVER INJURY IN RATS

ABSTRACT:

Chemotherapy for malignant tumours has diversified, and recognizing its side effects has become more important than ever. Capecitabine (Xeloda) was established as a treatment option in colorectal cancer in 2001, and more recently for adjuvant treatment of colon cancer and treatment of metastatic breast cancer, but this was associated with severe toxicities. The present work investigated the protective role of vitamin C against Capecitabine–induced liver toxicity in rats. Forty male albino rats were randomly divided into four groups of 10 animals each. Group I represents the control group; Group II were administrated Capecitabine (3 mg/m^2 twice daily) *via* gavage for two weeks. The animals of Group III received vitamin C (100 mg/kg BW) before Capecitabine administration; the animals of Group IV received vitamin C alone (100 mg/kg BW). At the end of the 2nd week, the general status of the rats, histopathology and Immunohistochemistry of the liver, and the levels of serum alanine aminotransaminase (ALT), aspartate aminotransaminase (AST), and alkaline phosphatase (ALP) levels were detected. The present results showed that Capecitabine caused significant increases in serum ALT, AST, and ALP. Also, the results of the present study showed that Capecitabine produced a severe inflammatory lesion to the liver compared to the control group. PCNA expression was increased in the liver of Capecitabine-treated rats. Administration of vitamin C exhibited significant reversal of Capecitabine-induced toxicity in the hepatic tissue. In conclusion, these results suggest that vitamin C has a protective role towards Capecitabine toxicity in the rat.

KEY WORDS:

Rat, hepatotoxicity, Immunohistochemistry, Capecitabine, Vitamin C

CORRESPONDENCE:

Mohamed SA. El-Gerbed

Department of Zoology, Faculty of Science, Damanhour University, Damanhour, Egypt

E-mail: m.elgerbed@yahoo.com

ARTICLE CODE: 06.01.15

INTRODUCTION:

Chemotherapy is one of the most widely-used interventions for treatment of cancer. The cytotoxic effect of cancer chemotherapy is not selective for cancer cells; it also affects the normal tissues. The amount of the damage and its severity is based on the type, amount and duration of drug used to treat the disease (Liu, 2009; Minami *et al*., 2010). One of the major limitations in the currently available treatment modalities for cancer is their side effects (Joensuu, 2008).

Chemotherapy agents can be divided into several categories based on factors such as how they work, their chemical structure, and their relationship to another drug. The most important categories of chemotherapeutics include alkylating agents (e.g., cyclophosphamide, ifosfamide, melphalan, busulphan), antimetabolites (e.g., 5-fluorouracil, capecitabine, methotrexate, gemcitabine), antitumour antibiotics (e.g., daunorubicin, doxorubicin, epirubicin), topoisomerase inhibitors (e.g., topotecan, irinotecan, etoposide, teniposide), and mitotic inhibitors (e.g., paclitaxel, docetaxel, vinblastine, vincristine) (Lamson and Brignall, 1999; Wu, 2006). Most the chemotherapeutic drugs target the cell cycle machinery relying on the difference in the frequency of cell division to differentiate between the cancer clones and normal cells. Within this process slow-growing cancer clones will survive and evolve into new fast-growing strains. Chemotherapy is able to kill off most of the susceptible tumour cells succeeding to send cancer into remission for weeks or months after which it reemerges as a more aggressive organism (Parris, 2005; Harless and Qiu, 2006).

Capecitabine (N4-pentiloxicarbonil-5'-desoxi-5- fluorcitidine) (Xeloda) is considered a standard treatment option in advanced colorectal cancer (CRC) (Cassidy *et al.*, 2008) and as adjuvant therapy in colon cancer (Haller *et al.*, 2010). Capecitabine (Xeloda) is an orally administered precursor of fluorouracil (5-FU), a fluoropyrimidine antimetabolite. It is converted through a series of enzymatic steps to 5-FU preferentially in tumour tissue, and also in the liver, by way of a three-step enzymatic

cascade (Miwa *et al*., 1998). Capecitabine is a relatively new agent, with FDA approval in 2001 for use as an alternative to the Mayo Clinic 5-FU/folinic acid regimen for metastatic colon cancer. It has since been approved for use in the adjuvant treatment of colon cancer, as well as for metastatic breast cancer. Capecitabine is also suitable for combination with a variety of agents, particularly those known to further up regulate thymidine phosphorylase (TP) in tumour tissue, such as paclitaxel, taxotere, and mitomycin-C (Sawada *et al.,* 1998; Endo *et al*., 1999; Ishitsuka, 2000).

Capecitabine itself is not cytotoxic, but it becomes effective after it has been converted to 5-FU in tumour cells (Schüller *et al*., 2000). However, as the use of capecitabine becomes more widespread, its side effects, including cardiotoxicity, appear to be similar to those of 5-FU (Van Cutsem *et al*., 2002; Kelly *et al*., 2013).

The common clinical side effects of Capecitabine include myelosuppression, diarrhea, vomiting and mucositis. Extensive investigations have been conducted on the hepatotoxicity of this anticancer drug. There is very limited information concerning with the effects of Capecitabine on the histology and enzyme activities of serum changes of the liver cells. Further, a variety of agents including antioxidants have been shown to attenuate the hepatotoxicity of Capecitabine. Like other chemotherapeutics, Capecitabine causes excessive reactive oxygen species (ROS) generation and also induces a decrease in plasma antioxidant levels, which may reflect a failure of antioxidant defence mechanism against oxidative damage. Much attention has been given to the possible role of antioxidants in protecting liver against chemotherapy-induced toxicity (Behling *et al*., 2006).

Vitamins have indispensable role in almost all bio- chemical reactions and they are ideal antioxidants able to increase tissue protection from oxidative stress due to their easy, effective and safe dietary administration in a large range of concentrations (Kanter *et al*., 2005). Vitamin C (ascorbic acid, VC), a known chelating agent with non-enzymatic antioxidant features, was reported to have the ability to protect cells from oxidative stress (Patra *et al*., 2001; Murugesan *et al*., 2005). It is the most important free radical scavenger in extracellular fluids, trapping radicals in the aqueous phase and protecting the biological membranes from peroxidative damage (Patra and Swarup, 2004; Rai *et al*., 2009). These properties of the Vitamin C are thought to provide many beneficial effects against organ damages. Thus, the aim of the present study was to investigate the possible protective effect of Vitamin C as an antioxidant using measurement of the activities of liver enzymes, and detecting the alterations of hepatic microscopy in Capecitabine-induced liver of rats.

MATERIAL AND METHODS:

Chemicals:

Capecitabine was obtained from CIPLA LTD Company. Vitamin C (as ascorbic acid) was obtained from Pharco Pharmaceutical Company, Alexandria, Egypt. Assay Biochemical assays commercially- available kits were purchased from Sigma Diagnostics, St. Louis, MO, USA. Immunohistochemistry kits were purchased from Lab vision thermo-scientific immunohistochemistry solutions.

Animals and treatment:

Healthy male albino rats, each weighing 150 ±7 g, were obtained from Veterinary Science Institute, Helwan, Cairo, Egypt. The animals were housed in plastic cages; exposed to a 12 h light/dark cycle. The animals were allowed to acclimatize in the laboratory environment for 10 days before start of the treatments. They were maintained on a standard rodent diet composed of 20% casein, 15% corn oil, 55% corn starch, 5% salt mixture, and 5% vitaminzed starch (Egyptian Company of Oils and Soap Kafr-Elzayat, Egypt), and water was available *ad libitum*. Forty rats were randomly divided into four groups, each of ten animals:

The first group (**G1)**:

The rats of this group served as controls; fed on a standard diet and given tap water.

The second group (**G2)**:

Capecitabine tablets (500 mg) were dissolved in 30 ml distilled water. The solution was administered orally at a dose of 2 ml 16 mg/BW twice daily for 14 consecutive days. The dose was calculated according to Paget and Barnes (1964).

The third group (G3),

The rats of this group orally administered Capecitabine (16 mg/ BW twice daily) plus vitamin C at a dose of 100 mg/kg BW, (Al-Shamsi *et al*., 2007) 24 h prior to Capecitabine, administration.

The fourth group (G4):

The rats of this group administrated vitamin C (100 mg/kg BW orally) once daily for 14 consecutive days.

The experimental protocols held on the animals were in accordance with the guides of the Animal Ethics Committee of Alexandria University.

Relative liver weight as a ratio of body weight (hepatosomatic index):

Body and liver weights of the control and treated rats were measured by employing an automatic balance (GX-600, Japan). Liver was removed and washed with ice-cold saline,

dried on filter paper and weighed immediately. The liver ratio was calculated with the following formula,

Organ ratio (%) = organ weight (g) × 100/body weight (g)

Biochemical assays:

All the rats were sacrificed and blood was collected, by carotid bleeding in centrifuge tubes. The serum was separated and used freshly for the assessment of liver function tests. For the biochemical study, serum Aspartate Transaminase (AST) and Alanine Transaminase (ALT) activities were measured according to the method of Reitman and Frankel (1957), by available kit. Alkaline Phosphatase (ALP) was assayed according to the method of Rec (1972).

Histopathological observations:

For histological study, the liver tissues were isolated from all the experimental rats and were gently rinsed with physiological saline solution (0.9% NaCl) to remove blood and debris adhering to the tissue. Small pieces of the liver were collected (at least five pieces) were taken from each rat, and then fixed in 10% neutral buffered formalin for proper fixation. Following fixation, the specimens were dehydrated, embedded in wax, and then sectioned to 5 µm thick. For histological examinations, the sections were stained with haematoxylin and eosin (Luna, 1968). After dehydration and clearing, the mounted slides were examined under photomicroscope. Six rats from each group were sacrificed for analyzing the hepatic histological examinations.

Immunohistochemical Staining:

Tissue samples from liver were fixed in 10% buffered neutral formalin solution. After the routine alcohol-xylol process, tissue samples were embedded in paraffin and sectioned in 5-6 µm. The tissue sections were cut 1–2 days prior to immunostaining to avoid potential problems in antigen recognition due to storage degradation of the cut tissue sections on glass slides (Prioleau and Schnitt, 1995). Proliferating cell nuclear antigen (PCNA) was detected in hepatocytes using the avidin-biotin peroxidase. Paraffin-embedded liver sections were deparaffinized and hydrated. Endogenous peroxidase activity was blocked by incubation with 3% hydrogen peroxide for 5 min. The Sections were incubated over night with PCNA monoclonal antibody (Dako Corporation, Carpentaria, CA) and washed with phosphate buffer saline (PBS) for 5 min. The monoclonal antibody was then linked with biotinylated goat antimouse IgG antibody (Daco, LASB Universal Kit) for 30 min. After being washed with PBS for 5 min, the sections were incubated with streptavidin conjugated peroxidase for 30 min. Brown nuclear stain was seen in positive cases of PCNA expression. The Sections were counter-stained with haematoxylin (Hsu *et al*., 1981). To evaluate PCNA labelling index, the data were analyzed using the image j IHC profiler software. The percentage of stained cells was counted in liver sections from each animal group, and non-overlapping fields and expressed as the number of PCNA positive cells/mm^2.

Statistical Analysis:

The values are expressed as mean± SE. The results were computed statistically SPSS software package (version 8) using one-way analysis of variance (ANOVA).

RESULTS:

Body and liver weights:

Death was not observed in any of the experimental groups during the experimental period. However, during the experiment, the rats of the control group and the Vitamin C-treated group did not show any sign of toxicity or death. However, Capecitabine-treated rats showed varying degrees of clinical signs. The signs included huddling, conjunctivitis, mild tremor, piloerection and diarrhoea. As shown in table 1, when compared to the control group, there was a significant ($p < 0.05$) decrease in the liver, as well as the body weight in the Capecitabine-treated rats after 14 days when compared with the control rats (Table 1). Animals given Capecitabine and vitamin C showed a partial increase in the body and liver weight ($p < 0.05$) (Table 1) compared to the controls. Vitamin C-treated group showed no significant changes in the body and liver weights.

Table 1. Body weight, liver weight, and relative liver weight of the control and experimental rats

Groups	Body weight			Absolute liver weight (g)	Relative liver weight (g/100 g body weight)
	Initial (g)	Final (g)	% Change		
Control	125.21 ± 2.14	122.12 ± 1.72 [a]	-2.46 ± 0.82 [a]	2.39 ± 0.02 [a]	1.95 ± 0.01 [a]
Capecitabine	132.62 ± 2.31	126.53 ± 2.54 [b]	-4.59 ± 1.31 [b]	1.96 ± 0.05 [b]	1.54 ± 0.01 [b]
Capecitabine + vitamin C	122.71 ± 1.33	123.61 ± 1.55 [b]	0.73 ± 002 [a]	2.25 ± 0.05 [c]	1.82 ± 0.03 [c]
vitamin C	116.17 ± 2.61	124.31 ± 2.71 [a]	7.01 ± 1.22 [c]	2.67 ± 0.02 [a]	2.14 ± 0.02 [a]

- Values are mean ± SE for eight rats in each group.
- Values not sharing common superscript letters (a-c) differ significantly at $p < 0.05$ (DMRT).

Biochemical results:

The control group was compared with the other groups at the end of the 2nd week. In addition, the Capecitabine-treated group was compared to the vitamin C individually or in combination with Capecitabine-treated groups. No statistically significant differences were

observed when vitamin C alone-treated groups were compared with the control group.

Administration of Capecitabine (3 mg/kg BW twice daily) caused abnormal liver functions in all the rats. Serum aspartate aminotransferase (AST), alanine aminotransferase (ALT) and alkaline phosphatase (ALP) levels increased significantly ($p < 0.05$) in the groups treated with Capecitabine (Table 2). On the other hand, AST, ALT, and ALP showed a significant decrease in sera of animals given Capecitabine and vitamin C. Treatment with vitamin C alone caused significant decreases ($p < 0.05$) in ALP, ALT, and AST activities as compared to the Capecitabine-exposed group.

Table 2. Effect of vitamin C on Capecitabine-induced alterations in the activities of biochemical parameters in liver of the control and experimental rats

Treatment	ALT (U/l)	AST (U/l)	ALP (U/l)
Control	32.52 ± 4.25[a]	42.83 ± 4.26[a]	26.31 ± 2.25[a]
Capecitabine	64.21 ± 6.45[b]	63.31 ± 5.38[b]	48.75 ± 4.41[b]
Capecitabine + vitamin C	33.22 ± 4.22[a]	41.78 ± 3.15[a]	28.26 ± 2.17[a]
vitamin C	34.82 ± 3.18[a]	44.05 ± 4.26[c]	24.14 ± 2.24[c]

- Values are mean ± SE for eight rats in each group.
- Values not sharing common superscript letters (a-c) differ significantly at $p < 0.05$.

Histological results:

The examination of the sections of the control rat liver clearly illustrates normal architecture; complete hepatic lobules with well normal polygonal or oval shaped nuclei with distinct portal triads. The liver cells are arranged in cordlike fashion, which are separated by sinusoids and the central vein was seen clearly (Fig. 1A). In the present study administration of Capecitabine induced many histological alterations. The normal structural organization of the hepatic lobules was impaired and the characteristic cord-like arrangement of the normal liver cells was lost. In addition, degenerated hepatocytes with vacuolated cytoplasm and rupture of sinusoidal endothelia were seen. Area of necrosis and infiltration by inflammatory cells were observed (Fig. 1B&C). Liver sections obtained from animals treated with Capecitabine and Vitamin C indicated an obvious degree of improvement with normal pattern, in comparison with the rats treated with Capecitabine (Fig. 1D). Vitamin C -treated rats showed normal hepatic histology as that of the control group (Fig. 1E).

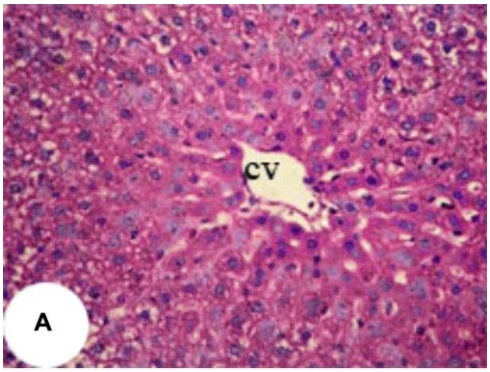

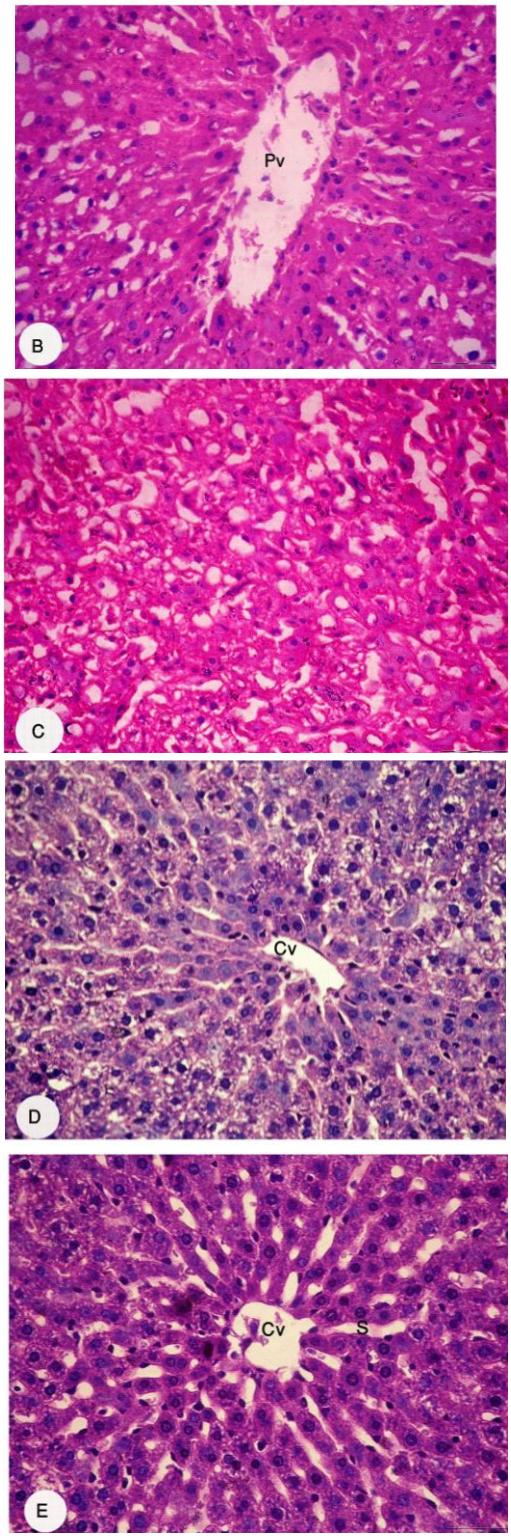

Fig. 1. Photomicrographs of haematoxylin- and eosin-stained sections of rat liver. (A & E): The control rats and animals treated with vitamin C, respectively show normal cords architecture radiating from the central vein (CV) which is lined with endothelial cells, the hepatic cords are separated by the hepatic sinusoids (S) lined by Kupffer cells (KC). (B & C): Animals administered with Capecitabine showed severe signs of liver damage; hepatocytes with vacuolated cytoplasm, some hepatocytes showed microvesicular steatosis, dilated hepatic sinusoids (S), others with binucleated cells and extensive necrosis, the central vein (CV). (D): Rats treated with Capecitabine and vitamin C, show the same histological observations as in the liver of the control animals.

Expression of PCNA:

Examination of liver sections of control and group 4 (orally administrated 100 mg/kg BW vitamin C, once daily for 14 consecutive days) indicated that few nuclei displayed faint stain of PCNA (Fig. 2A&E). However, PCNA labelling was elevated in Capecitabine group; they showed stimulation of DNA synthesis and strong positive stained nuclei (Fig. 2B&C). On the other hand, the liver sections of rats that treated with Capecitabine and vitamin C (G3) showed more positive stain in some nuclei but less than that of G2 that administered Capecitabine only (Fig. 2D & Table 3).

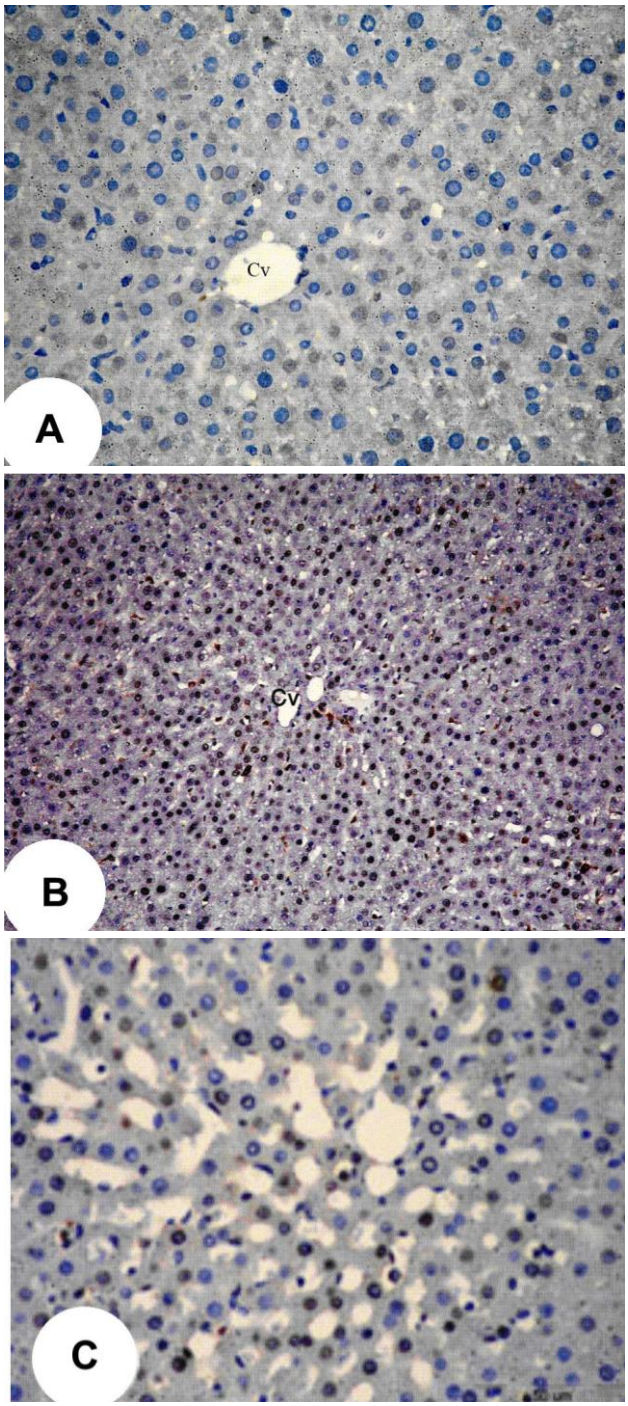

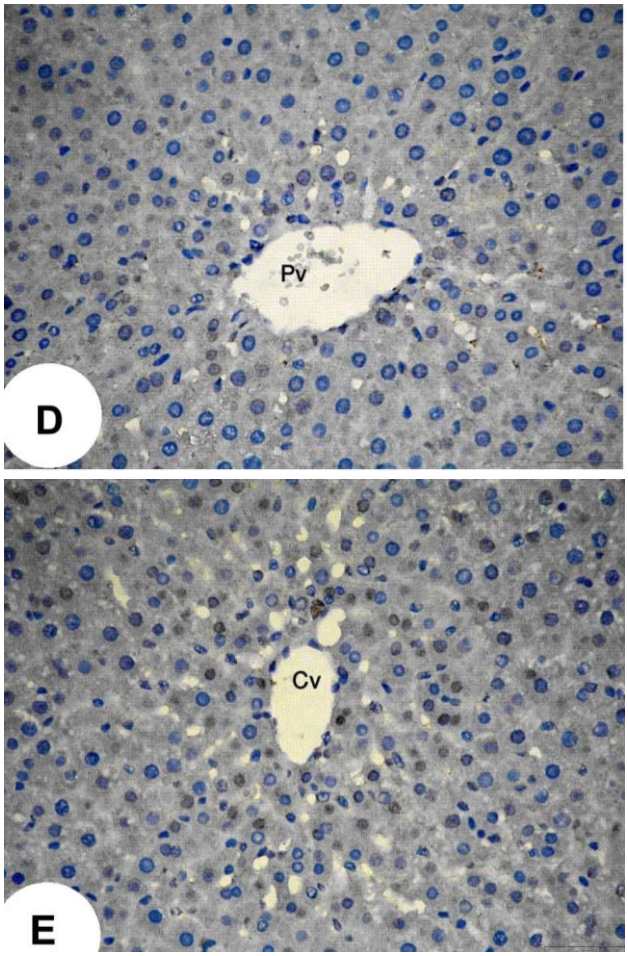

Fig. 2. (A & E): Liver sections a control rat and animal treated with vitamin C, respectively show few cells with proliferating cell nuclear antigen (PCNA) expression, (B & C): photomicrographs of liver sections of rats after treatment with Capecitabine showing large number of cells with PCNA expression, (E): a liver section of rat after treatment with Capecitabine and vitamin C show weak positive immunostaining with PCNA.

Table. 3. The liver PCNA labelling protein index in the level of immune staining contribution in different experimental groups

Groups	Percentage contribution of Positive
Control	8.67 ± 1.O3[a]
Capecitabine	23.42 ± 6.83[b]
Capecitabine + vitamin C	15.84 ± 3.32[c]
vitamin C	11.21 ± 1.22[a]

Data are means ± SE. Means in the same column with different superscript letters are significantly different, $P < 0.05$ (one-way ANOVA).

DISCUSSION:

The liver plays an astonishing array of vital functions in maintaining, performing and regulating homeostasis of the body. It is involved with almost all the biochemical pathways to growth, fight against diseases, nutrient supply, energy provision and reproduction (Sharma *et al*., 1991).

Hepatotoxicity implies chemical-driven liver damage. Certain medicinal agents, when

taken in overdoses and sometimes even when introduced within the therapeutic ranges, may injure the organ.

The present study revealed that Capecitabine-induced liver injury in rats. Hepatotoxicity in this study was gauged by liver and body weight loss. The loss of the body weight was due to loss of skeletal muscles and adipose tissue as previously suggested by Devlin (1997). Moreover, the reduction in the body weight of the animals of this study may be due to decreased food intake. These results were in accordance with those of Lee *et al*. (2007) who indicated that treatment of mice with cisplatin resulted in liver weight loss and a significant reduction of its percentage to the total body weight in mice. It is believed that intestinal conversion of capecitabine to cytotoxic agent 5′-deoxy-5-fluorocytidine (5′-DFCR) is responsible for gastrointestinal adverse events (GI AEs), but the exact mechanism is not yet known (Saif *et al*., 2008; Miwa *et al*., 1998; Schüller *et al*., 2000). The decrease of body weight of Capecitabin-treated rats might be due to gastrointestinal toxicity and dysfunction or due to of the anorexic effect of the drug and the increased metabolic rate, which were considered side effects of the chemotherapy (Ershler, 2006).

The hepatic cells participate in a variety of metabolic activities and contain a host of enzymes. The liver functions are in a coordinated way with various systems of the body and any disease involving this organ has a serious and far-reaching effect not only on the liver itself but also on other organs and systems. The present study showed a significant hepatic damage elicited by the elevated level of serum marker enzymes, AST and ALT in rats with Capecitabine treatment alone in comparison with the control group. The increased serum levels of the hepatic markers have been attributed to the liver injury, because these enzymes are released into circulation in case of cellular damage (Lin *et al*., 2000). The present data are in agreement with Brandolt *et al*. (2011) who reported that all the patients from both sexes had higher levels of ALT and AST when using capecitabine. The same result was also obtained by Sakr *et al*. (2011) who reported that Adriamycin induced hepatotoxicity in albino rats. In addition, Injac *et al*. (2008) reported that treatment with doxorubicin caused significant changes in the serum level of AST, ALT, aspartate, LDH, and hydroxybutyrate dehydrogenase. These results are in agreement with the previous reports on 5-FU-induced hepatotoxicity (Zorzi *et al*., 2007; Mikalauskas *et al*., 2011) who reported that when 5-FU has been given intravenously for the treatment of breast and gastrointestinal cancers, it is metabolized in tissues to its active form, 5-fluoro-deoxyuridine monophosphate, which inhibits thymidylate synthase. 5-FU is also catabolized primarily in the liver, as dihydrouracil, and the reduced compound is then cleaved to α-fluoro-β-alanine, ammonia, urea, and carbon dioxide which cause hepatotoxicity. Administration of vitamin C attenuated the increased levels of the serum enzymes, produced by Capecitabine and caused a subsequent recovery towards normalization in the form of recovery of serum parameters by different test samples. This suggests that vitamin C is beneficial for liver regeneration and for reverse of liver injury.

Treating rats with Capecitabine caused many histological alterations including leucocytic infiltration added to blood vessels congestion and necrosis in the liver. In addition, these results showed an intense cytoplasm vacuolization of the hepatocytes and widening of the sinusoids. These results agree with those obtained by Cetin *et al*. (2011) who reported severe degeneration and necrosis in hepatocytes, dilatation and congestion of sinusoids, increased number of Kupffer cells and inflammatory cell infiltration in the hepatic portal areas in rats treated with cisplatin. Similar observations were reported in the liver of rats treated with 5-FU, cisplatin and doxorubicin (El-Sayyad *et al*., 2009).

Sakr *et al*. (2011) observed that Adriamycin administration to rats resulted in dilatation and congestion of the hepatic sinusoids and of the intrahepatic veins. The present results also agree with those obtained by Klatskin and Ocean (1993) who suggested that dilatation of the blood sinusoids would be due to the direct toxic effect of the toxin on the blood sinusoids leading to their dilatation. These results are in agreement with the previous reports on 5-FU-induced hepatotoxicity (Mikalauskas *et al*., 2011). However, treatment with vitamin C decreased hepatotoxicity features in rat liver, suggesting that vitamin C provided protection against Capecitabine-induced liver injury.

Most non-growing cells contain little PCNA mRNA and protein (Kelman, 1997). Thus, activated synthesis is necessary for the purpose of DNA repair after genotoxic insult in populations of non-growing cells. PCNA is well-established as a useful marker for replication of DNA (Dierendonck van *et al*., 1991). In the present study, PCNA rates were markedly elevated in the liver cells of Capecitabine-treated rats as compared with the control rats. This may be attributed to the response of hepatocytes to liver damage.

The proliferating cell nuclear antigen (PCNA) is a useful tool for studying the proliferating cells in normal tissues, and possible apparent expression in neoplasm indicating division and proliferation of the cells. Previous studies demonstrated that the PCNA labeling index increased sequentially

from normal tissue through the premalignant stage to carcinoma of various tumours (Roy *et al*., 2007). The PCNA values were found to affect prognosis adversely, where it is an auxiliary protein present during the G1- the latest phase and S phase. The increased PCNA of HCC is closely correlated with the advanced histologic grades, pathologic stages, and poor patients' outcome (Zafar and Ali, 2013).

Intake of antioxidant vitamins which are widely distributed in fruits could be beneficial in protection against hepatotoxicity (William, 1995). Vitamin C is a well-known antioxidant, which can protect the body from damage caused by free radicals that can be generated during normal metabolism as well as through exposure to toxins and carcinogens (Banerjee *et al*., 2009). Many studies reported that vitamin C supplementation could ameliorate cisplatin-induced acute renal failure in mice (Ajith *et al*., 2007) and protected cells against radical mediated lipid peroxidation (Cuddihy *et al*., 2008). Other articles suggested that vitamin C reduced the oxidative stress-induced renal failure (Ferretti *et al*., 2008).

The present results showed that treating rats with Capecitabine and vitamin C improved the histopathological and enzyme activities changes induced in the liver by Capecitabine. This indicated the effectiveness of vitamin C in prevention of Capecitabine hepatotoxicity, and this runs in agreement with Atasayar *et al.* (2009) who demonstrated that combined treatment of vitamin C and E with a single acute dose (toxic dose) of cisplatin (7.5 mg/kg) was able to normalize the histopathological alterations induced by cisplatin on kidney when compared with the cisplatin-treated group. The present results agree with those obtained by Chinoy *et al.* (2004) who revealed that ascorbic acid (vitamin C) and vitamin E are capable of completely, or almost completely, mitigating liver toxicity in mice induced by fluoride and aluminium.

The mechanism by which vitamin C decreases the hepatotoxicity induced by 5-FU, is embodied in the fact that vitamin C might ameliorate the oxidative damage by decreasing lipid peroxidation and altering the antioxidant defence system (El-Gendy *et al*., 2010) or by denoting electrons to free radicals and quenching their reactivity (Bendich, 1990). In addition, ascorbate prevents hepatic glutathione depletion in chemical-induced hepatotoxicity in mice, in which glutathione acted as intracellular free-radical scavengers and protected cells against radical mediated lipid peroxidation (Cuddihy *et al*., 2008).

In conclusion, the findings of the present study clearly indicate that Capecitabine induced histopathological and enzyme activities of serum changes in the hepatocytes of rats, and that vitamin C has a partial protective role in Capecitabine-induced hepatic injury. So it may be useful to use vitamin C as an adjunctive supplementation to minimize the toxic side-effects of Capecitabine

.

REFERENCES:

Ajith TA, Nivitha V, Usha S. 2007. Zingiber officinale Roscoe alone and in combination with alpha-tocopherol protect the kidney against cisplatin-induced acute renal failure. Food Chem. Toxicol., 45(6): 921–927.

Al-Shamsi M, Amin A, Adeghate E. 2007. The Effect of Vitamin C on the Metabolic Parameters of Experimental Diabetes Mellitus. Am. J. Pharmacol. Toxicol., 2(1): 4-9.

Atasayar S, Gürer-Orhan H, Orhan H, Gürel B, Girgin G, Özgüneş H. 2009. Preventive effect of amino guanidine compared to vitamin E and C on cisplatin-induced nephrotoxicity in rats. Exp. Toxicol. Pathol., 61(1): 23–32.

Banerjee P, Bhattacharyya SS, Bhattacharjee N, Pathak S, Boujedaini N, Belon P, Khuda-Bukhsh AR. 2009. Ascorbic acid combats arsenic-induced oxidative stress in mice liver. Ecotoxicol. Environ. Saf., 72(2): 639–649.

Behling EB, Sendão MC, Francescato HD, Antunes LM, Costa RS, Bianchi Mde L. 2006. Comparative study of multiple dosage of quercetin against cisplatin-induced nephrotoxicity and oxidative stress in rat kidneys. Pharmacol. Rep., 58(4): 526-532.

Bendich A. 1990. Antioxidant micronutrients and immune responses. Ann. N.Y. Acad., Sci. 587: 168–180.

Brandolt GL, Ely LS, Engroff P, Almeid TW, Azambuja AA, Gomes I, de Carli GA, Morrone FB. 2011. BToxicity of capecitabine compared with 5-fluorouracil in elderly patients with breast or gastrointestinal tract cancer. Appl. Cancer Res., 31(4): 131-137.

Cassidy J, Clarke S, Diaz-Rubio E, Scheithauer W, Figer A, Wong R, Koski S, Lichinitser M, Yang TS, Rivera F, Couture F, Sirzen F, Saltz L. 2008. Randomized phase III study of capecitabine plus oxaliplatin compared with fluorouracil/folinic acid plus oxaliplatin as first-line therapy for metastatic colorectal cancer. J. Clin. Oncol., 26(12): 2006–2012.

Cetin A, Arslanbas U, Saraymen B, Canoz O, Ozturk A, Sagdic O. 2011. Effects of grape seed extract and origanum onites essential oil on cisplatin-induced hepatotoxicity in rats. Int. J. Hematol. Oncol., 21(3): 133–139.

Chinoy NJ, Sharma AK, Patel TN, Memon R, Jhala DD. 2004. Recovery from fluoride and aluminium induced free radical liver toxicity in mice. Fluoride, 37(4): 257–263.

Cuddihy SL, Parker A, Harwood T, Vissers M, Winterbourn C. 2008. Ascorbate interacts with reduced glutathione to scavenge phenoxyl radicals in HL60 cells. Free Radical Biol. Med., 44(8): 1637–1644.

Devlin TM. 1997. Text book of biochemistry: with clinical correlation, 4th Ed. New York: John Wiley and Sons Inc., pp. 553.

Dierendonck van JH, Wijsman JH, Keijzer R, van de Velde CJH, Cornelisse CJ. 1991. Cell-cycle-related staining patterns of anti-proliferating cell nuclear antigen monoclonal antibodies. Am. J. Pathol., 138(5): 1165–1172.

El-Gendy KS, Aly NM, Mahmoud FH, Kenawy A, El-Sebae AK. 2010. The role of vitamin C as antioxidant in protection of oxidative stress induced by imidacloprid. Food Chem. Toxicol., 48(1): 215–221.

El-Sayyad HI, Ismail MF, Shalaby FM, Abou-El-Magd RF, Gaur RL, Fernando A, Raj MH, Ouhtit A. 2009. Histopathological effects of cisplatin, doxorubicin and 5-flurouracil (5-FU) on the liver of male albino rats. Int. J. Biol. Sci., 5(5): 466–473.

Endo M, Shinbori N, Fukase Y, Sawada N, Ishikawa T, Ishitsuka H, Tanaka Y. 1999. Induction of thymidine phosphorylase expression and enhancement of efficacy of capecitabine (Xeloda) or 5′-deoxy-5-fluorouridine (Furtulon) by cyclophosphamide in mammary tumor models. Int. J. Cancer, 83(1): 127-134.

Ershler WB. 2006. Capecitabine use in geriatric oncology: An analysis of current safety, efficacy, and quality of life data. Crit. Rev. Oncol. Hematol., 58: 68-78.

Ferretti G, Bacchetti T, Masciangelo S, Pallotta G. 2008. Lipid peroxidation in haemodialysis patients: effect of vitamin C supplementation. Clin. Biochem., 41(6): 381–386.

Haller DG, Cassidy J, Tabernero J, Maroun F. De Braud G, Price TJ, Van Cutsem E, Hill M, Gilberg F, Schmoll H. 2010. Efficacy findings from a randomized phase III trial of capecitabine plus oxaliplatin versus bolus 5-FU/LV for stage III colon cancer (NO16968): No impact of age on disease-free survival (DFS). J. Clin. Oncol., 28(15): 3521-3627.

Harless W. and Qiu Y. 2006. Cancer: a medical emergency. Med. Hypotheses, 67(5): 1054–1059.

Hsu SM, Raine L, Fanger H. 1981. Use of avidin-biotinperoxidase complex in immunoperoxidase techniques: a comparison between ABC and unlabeled antibody (PAP) procedures. J. Histochem. Cytochem., 29(4): 577–580.

Injac R, Perse M, Obermajer N, Djordjevic-Milic V, Prijatelj M, Djordjevic A, Cerar A, Strukelj B. 2008. Potential hepatoprotective effects of fullerenol C60(OH)24 in doxorubicininduced hepatotoxicity in rats with mammary carcinomas. Biomaterials, 29(24-25): 3451–3460.

Ishitsuka H. 2000. Capecitabine: preclinical pharmacology studies. Invest. New Drugs, 18(4): 343-354.

Joensuu H. 2008. Systemic chemotherapy for cancer: from weapon to treatment. Lancet Oncol., 9(3): 304.

Kanter M, Coskun O, Armutcu F, Uz YH, Kizilay G. 2005. Protective effects of vitamin c, alone or in combination with vitamin a, on endotoxin-induced oxidative renal tissue damage in rats. Tohoku J. Exp. Med., 206(2): 155-162.

Kelly C, Bhuva N, Harrison M, Buckley A, Saunders M. 2013. Use of raltitrexed as an alternative 5-fl uorouracil and capecitabine in cancer patients with cardiac history. Eur. J. Cancer, 49(10): 2303-2310.

Kelman Z. 1997. PCNA: structure, functions and interactions. Oncogene. 14(6): 629–640.

Klatskin G, Ocean HO. 1993. Histopathology of the Liver, vol. 2. Oxiford University Press, Oxford and New York, pp. 768.

Lamson W, Brignall MS. 1999. Antioxidants in cancer therapy; their actions and interactions with oncologic therapies. Altern. Med. Rev., 4(5): 304–329.

Lee CK, Park KK, Lim SS, Park JH, Chung WY. 2007. Effects of the licorice extract against tumor growth and cisplatin-induced toxicity in a mouse xenograft model of colon cancer. Biol. Pharm. Bull., 30(11): 2191–2195.

Lin SC, Chung TC, Lin CC, Ueng TH, Lin YH, Lin SY, Wang LY. 2000. Hepatoprotective effects of Arctium lappa on carbon tetrachloride and acetaminophen-induced liver damage. Am. J. Chin Med., 28(2): 163–173.

Liu FS. 2009. Mechanisms of chemotherapeutic drug resistance in cancer therapy - a quick review. Taiwan. J. Obst. Gyn., 48(3): 239–244.

Luna LG. 1968. Manual of histologic staining methods of the armed forces institute of pathology, 3rd ed. McGraw-Hill, New York, pp. 259.

Mikalauskas S, Mikalauskiene L, Bruns H, Nickkholgh A, Hoffmann K, Longerich T, Strupas K, Büchler MW and Schemmer P. 2011. Dietary glycine protects from chemotherapy- induced hepatotoxicity. Amino Acids, 40(4): 1139-1150.

Minami M, Matsumoto S, Horiuchi H. 2010. Cardiovascular sideeffects of modern cancer therapy. Circ. J. 74(9): 1779–1786.

Miwa M, Ura M, Nishida M, Sawada N, Ishikawa T, Mori K, Shimma N, Umeda I, Ishitsuka H. 1998. Design of a novel oral fluoropyrimidine carbamate, capecitabine, which generates 5-fluorouracil selectively in tumors by enzymes concentrated in human liver and cancer tissue. Eur. J. Cancer, 34(8): 1274-1281.

Murugesan P, Muthusamy T, Balasubramanian K, Arunakaran J. 2005. Studies on the protective role of vitamin C and E against polychlorinated biphenyl(Aroclor1254)-induced oxidative damage in Leydig cells. Free Radical Res., 39 (11): 1259–1272.

Paget GE, Barnes JM. 1964. Evaluation of drug activities, pharmacometrics. In Lawrance, D.R., Bacharach, A.L. (Eds). vol. I. Academic press, New York, pp. 161.

Parris GE. 2005. Clinically significant cancer evolves from transient mutated and/or aneuploid neoplasia by cell fusion to form unstable syncytia that give rise to ecologically viable parasite species. Med. Hypotheses, 65(5): 846-850.

Patra RC, Swarup D, 2004. Effect of antioxidant ascorbic acid, l-methionine or α tocopherol

alone or along with chelator on cardiac tissue of lead-treated rats. Vet. Arch., 74 (3): 235-244.

Patra RC, Swarup D, Dwivedi SK. 2001. Anti-oxidant effects of a tocopherol, ascorbic acid and L-methionine on lead-induced oxidative stress of the liver, kidney and brain in rats. Toxicology, 162 (2): 81–88.

Prioleau J, Schnitt SJ. 1995. p53 antigen loss in stored paraffin slides. N. Engl. J. Med., 332(22): 1521–1522.

Rai DK, Rai PK, Rizvi SI, Wata IG, Sharma B. 2009. Carbofuran-induced toxicity in rats: protective role of vitamin C. Exp. Toxicol. Pathol., 61(6): 531–535.

Rec. G. 1972. Optimised Standard Colorimetric Methods. J. Clin. Chem. Clin. Biochem., 10: 182.

Reitman S, Frankel S. 1957. A colorimetric method for the determination of serum glutamic oxalacetic and glutamic pyruvic transaminases. Am. J. Clin. Pathol., 1957; 28(1): 56–63.

Roy S, Roy Choudhury S, Mukherjee SK, Sengupta DN. 2007. Tobacco proliferating cell nuclear antigen binds directly and stimulates both activity and processivity of ddNTP-sensitive mungbean DNA polymerase. Arch. Biochem. Biophys., 468(1): 22-31.

Saif MW, Katirtzoglou NA, Syrigos KN. 2008.Capecitabine: an over view of the side effects and their management. Anti-cancer Drug., 19(5): 447−464.

Sakr SA, Mahran HA, Lamfon HA. 2011. Protective effect of ginger (*Zingiber officinale*) on adriamycin–induced hepatotoxicity in albino rats. J. Med. Plant Res., 5(1): 133–140.

Sawada N, Ishikawa T, Fukase Y, Nishida M, Yoshikubo T, Ishitsuka H. 1998. Induction of thymidine phosphorylase activity and enhancement of capecitabine efficacy by taxol/taxotere in human cancer xenografts. Clin. Cancer Res., 4(4): 1013-1019.

Schüller J, Cassidy J, Dumont E, Roos B, Durston S, Banken L, Utoh M, Mori K, Weidekamm E, Reigner B. 2000. Preferential activation of capecitabine in tumor following oral administration to colorectal cancer patients. Cancer Chemother. Pharmacol., 45(4): 291-297.

Sharma A, Chakraborti KK, Handa SS. 1991. Anti-hepatotoxic activity of some Indian herbal formulations as compared to silymarin. Fitoterapia, 62: 229-235.

Van Cutsem E, Hoff PM, Blum JL, Abt M, Osterwalder B. 2002. Incidence of cardiotoxicity with the oral fl uoropyrimidine capecitabine is typical of that reported with 5-fl uorouracil. Ann. Oncol., 13(3): 484-485.

William C. 1995. Healthy eating: clarify advice about fruit and vegetables. BMJ, 310(6992): 1453–1455.

Wu XZ. 2006. A new classification system of anticancer drugs— based on cell biological mechanisms. Med. Hypotheses, 66(5): 883–887.

Zafar H, Ali S. 2013. Boron inhibits the proliferating cell nuclear antigen index, molybdenum containing proteins and ameliorates oxidative stress in hepatocellular carcinoma. Arch. Biochem. Biophys., 529(2): 66-74.

Zorzi D, Laurent A, Pawlik TM, Lauwers GY, Vauthey JN, Abdalla EK. 2007. Chemotherapy-associated hepatotoxicity and surgery for colorectal liver metastases. Br. J. Surg., 94(3): 274-286.

الدور الوقائى لفيتامين C ضد الإصابة المستحثة بمادة كابسيتابين فى كبد الجرذان

محمد سعد الله الجربيد

قسم علم الحيوان، كلية العلوم، جامعة دمنهور، مصر

تنوع العلاج الكيميائي للأورام الخبيثة، والتعرف على آثاره الجانبية أصبح أكثر أهمية من أي وقت مضى. كابسيتابين (Xeloda) أصبح علاجًا لسرطان القولون والمستقيم في عام 2001، ومؤخرا كعلاج مساعد لسرطان القولون وعلاج سرطان الثدي النقيلي، ولكن يمكن أن تترافق مع سمية شديدة. وكان الغرض من هذه الدراسة توصيف الدور الوقائي لفيتامين C ضد السمية المستحثة بواسطة كابسيتابين في كبد الجرذان. تم تقسيم أربعين من ذكور الجرذان البيضاء عشوائيا إلى أربع مجموعات (ن = 10 / مجموعة). المجموعة الأولى: تمثل المجموعة الضابطة. المجموعة الثانية أعطيت كابسيتابين (3 مجم / م^2 مرتين يوميا) من خلال أنبوب تغذية لمدة أسبوع. تلقت المجموعة الثالثة: فيتامين C (100 مجم/كيلو جرام) قبل كابسيتابين. تلقت المجموعة الرابعة: فيتامين C فقط (100 مجم/كيلو جرام). وقد تم فى هذه الدراسة قياس العديد من المؤشرات مثل تقييم النشاط الإنزيمى. أيضا تم تقييم التركيب المجهري لأنسجة الكبد بما في ذلك التركيب النسيجي والدراسات المناعية بواسطة المجهر الضوئى. وأظهرت النتائج التي توصلنا اليها تسبب كابسيتابين فى زيادة كبيرة ملحوظة فى أنشطة انزيمات الكبد فى مصل الدم مثل ALT، AST و ALP. كما أظهر الفحص النسيجى بالمجهر الضوئى فى هذه الدراسة أن مجموعة كابسيتابين تنتج مجموعة متنوعة من الإصابات التي تتراوح بين الالتهابات الشديدة وتنخر للخلايا الكبدية. وقد لوحظت تغييرات عديدة متمثلة فى تلف الخلايا مقارنة مع مجموعة التحكم. قد صاحب علاج الحيوانات بفيتامين C تحسن واضح فى الصفات التشريحية المرضية التي تحدثها مادة كابسيتابين. وتشير هذه النتائج إلى أن فيتامين C ذو كفاءة في علاج الآثار فى كبد الفئران وقد ساهم في تخفيف الضرر فى تلف الكبد الناجم عن مادة كابسيتابين.

المحكمون:

أ.د. منير عز الدين الجنزوري قسم علم الحيوان، علوم عين شمس

أ.د. صابر عبد الرحمن صقر قسم علم الحيوان، علوم المنوفية